

CLINICAL REPORT



Treatment of the peripheral radiculopathy
with TENS: report of three clinical cases

Dr. Aldo Vasta

Treatment of the peripheral radiculopathy with TENS: report of three clinical cases



Dr. Aldo Vasta
Surgeon
Scientific consultant
EME s.r.l. Pesaro

In this paper there have been examined three cases in which radiculopathy of the cervical and lumbar rachis were successfully treated using the transcutaneous electric nerve stimulation (TENS) in addition to or in the place of manipulative therapy and spinal mobilization. The characteristics of TENS applied to the cases, the indications for their use and the application procedures have also been reviewed in this paper.

Keywords: TENS, burst, chiropractic, manipulation, spinal mobilization, Combined.

INTRODUCTION

The transcutaneous electric nerve stimulation (TENS) is being applied more and more for the treatment of acute and chronic pain. The actual concept of afferent stimulation techniques (often called neuromodulation) for pain management was created in 1965 with a publication by Melzack and Wall and the spinal gate-control theory.

This theory postulates that the activity in the large primary afferent proprioceptive myelinated fibers (fibers A), that work through the inhibitory circuits in the laminae of the dorsal horn, inhibits the transmission of activities in the small afferent unmyelinated fibers of the primary pain (fibers C), thus arresting messages of pain sent through the gate. The TENS was conceived to deliver a sensory stimulation rather than a motor stimulation, thus affecting sensorial ways.

A fundamental principle of this action is that the fibers of big dimensions can be stimulated selectively setting the mechanism of the gate in motion; thus, the activity of the small-diameter fibers is blocked.

Besides, there is experimental proof that hints to the fact that the analgesic effect of TENS might be modulated by means of releasing endorphinergic substances by the system of the endogenous opioids.

CHARACTERISTICS OF THE STIMULATING DEVICE USED

An electrotherapeutic stimulating system, equipped with all various types of TENS, model Combined by Medical Italia from Pesaro was used to supply transcutaneous electric nerve stimulation (TENS). The system of this device allows to set all stimulation parameters independently: frequency (from 10 to 500 Hz), impulse width and supplied power (in mA).



Fig.1: Stimulating device used for the treatment. By courtesy of EME-Medical Italia (Pesaro).

CASE REPORTS

Three cases of patients suffering from pain of rachis-related typology due to spondilotic cervical and lumbar processes of the vertebral column have been reviewed.

The cervical spondylosis or cervical arthrosis is a degenerative chronic condition of the cervical rachis that affects the vertebral bodies, intervertebral disks of the neck (for example in the form of slipped disk) and also the content of the spinal channel (nerve roots and/or of the spinal marrow). The cervical spondylosis includes also degenerative modifications of the joint facets, of the longitudinal ligaments and of the yellow ligament.

The cervical spondylosis, very frequent between C5-C6 and C6-C7, progresses with age and it often affects spaces between disks. The chronic cervical degeneration is the most common cause of the progressive compression of the spinal marrow and of the nerve root.

The deformations caused by cervical spondylosis can cause stenosis of the spinal channel, of the lateral recess and foramina. The stenosis of the spinal channel can lead to myelopathy, whereas the latter two can cause radiculopathy.

The intervertebral disks lose hydration and elasticity with age, leading to cracks and fissure. The surrounding ligaments lose elastic properties and develop traction spurs. The disk subsequently collapses as a result of mechanical incompetence, causing the annulus to bulge outward with consequences also on the facets. This change, in turn, increases motion at that spinal segment and further hastens the damage to the disk. Thus, herniation may occur. Acute disk herniation may worsen chronic spondylosis.

With herniation, the cross-sectional area is narrowed. This effect may be accentuated by hypertrophy of the facet joints and of the yellow ligament. Marginal osteophytes begin to develop and new bony outgrowths form. The vertebral bodies adjacent to the level of the degenerating disk degenerate, causing weakness; the vertebral column becomes more fragile, vascular restriction and also myelopathy and radiculopathy may appear.

It has been proved that disk space, formation of osteophytes and lumbar pain are directly interconnected.

CASE 1

M. S., a 68-year-old man, had been suffering from considerable pain to the buttocks and right hip for a long time (about 5 months); this, in turn, has made it difficult for him to walk, as he hardly can bear the load on the right side. The pain increased highly when the patient lied in bed and the sleep was disturbed.

The examination showed a moderate decrease of flexion and extension capacities of the lumbar rachis and an increase in pain at the right hip during extension. Upon palpation of the spiny apophyses of L5-S1 and L4-L5 the patient felt rather strong pain. Also the points of Valleix were painful down to the right calf and to left buttock. Muscle strength, reflexes and sensitivity were at normal levels. Positive Dandy sign to the right. Plantar response was decreased to the right.

Radiographic examination of the lumbar rachis showed a generalized degenerative illness of the disk with considerable decreasing of the disk spaces and formation of osteophytes (syndesmophytes) at the level L4-L5 and L5-S1 (Picture 4).

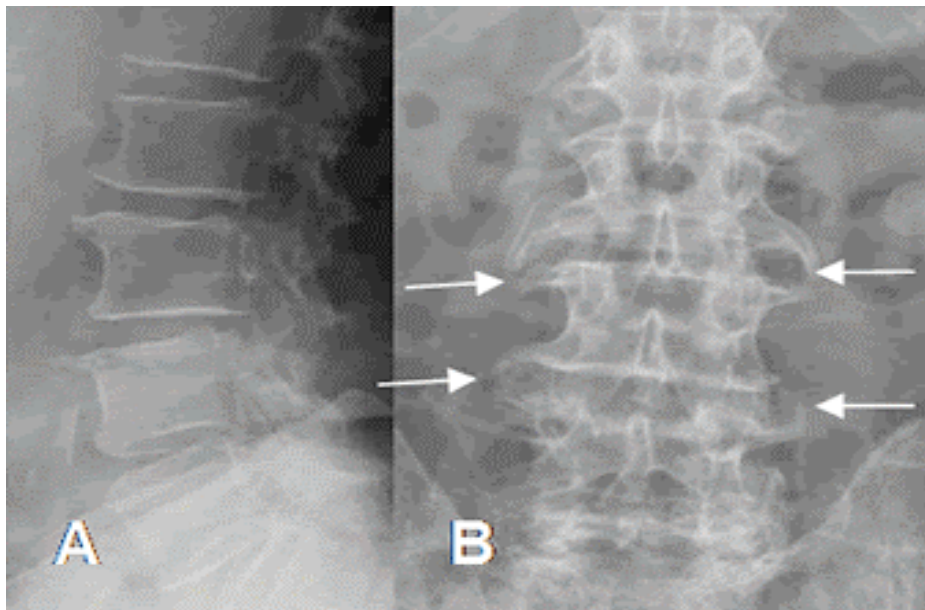


Fig.2: Syndesmophyte. A: Rx in lateral projection and B: Lumbar Rx in projection AP. Multiple lumbar osteophytosis with formation of syndesmophytes and shrinkage of disk spaces at L4.L5 and L5-S1.

The diagnosis of this case was chronic lumbosciatalgia with neurogenic intermittent claudication.

The treatment in this case consisted of 15 sessions of mobilization and light joint manipulation of the lumbosacral rachis and joint facets, followed after about 7 days by a cycle of treatments with conventional TENS. The electrodes, adhesive type (in this case "back electrodes" type at paraspinal level) were applied, like in the previous cases, in the following manner: at paraspinal level L4-L5, at the level of the point of Valleix on the right buttock (positive) and at the level of the popliteal fossa (negative: 2° channel).

The stimulating TENS unit was set at 300Hz and 110 usec for 20 minutes until the patient would feel a minimum muscle tensing and strong tingling. After 6 sessions pain was significantly reduced and also standing upright and walking improved in time.

CASE 2

M. P., a 66-year-old woman who had been involved in a road accident about 2 months before examination. About 10 days after the incident she was affected by cervicalgia radiating into lateral region of the arm and tingling of the arm and the left hand.

In the objective examination a total reduction of cervical rachis, especially in flesso-extension, was reported. The foraminal compression tests reproduced the pain in the left side of the neck, shoulder and arm.

Patient felt pain upon palpation on C4-C7 uninjured cranial nerves. Muscular strength, reflexes and sensitivity of the upper limbs were at normal level, whereas plantar response was decreased. The radiological examination of the cervical rachis of the patient showed a degenerative disk pathology at an advanced stadium at the level C5-C6 with prominent posterior osteophytes.

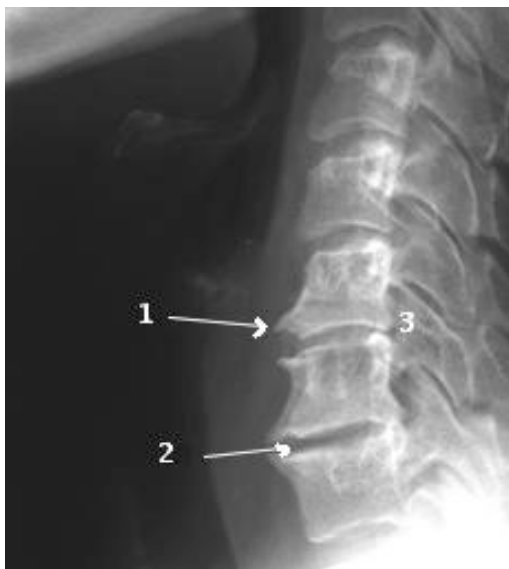

Fig.3.: It can be seen 1) marginal osteophytosis, in lateral projection it appears like bone spurs. The marginal osteophytosis sensibly reduces the diameter of the medullar channel, narrowing of one or more intervertebral spaces 2) reduction of the intersomatic space between two vertebrae (discopathy), 3) narrowing of connecting foramina 4) Increase of the physiological lordosis.

Therefore, cervical radiculopathy with posterior joint dysfunction was diagnosed.

The patient was treated daily during 15 days with passive and active light joint mobilization and TENS. The electrodes were applied on the left side on the cervical rachis (positive pole), on the trapezium muscle (on the sore point) and on the posterolateral region arm on the sore points, according to feedback from the patient.

Every treatment session lasted 25 minutes; the stimulating unit was set to modulated mode (frequency 300Hz, impulse duration 110usec, asymmetrical wave type).

At the end of the treatment the patient reported of a sensible improvement and increase of the joint mobility of the cervical rachis in all directions, without pain.

CASE 3

S. P. is a woman who had been suffering for about 11 years from pain to the arm and to the neck on the right side down to the elbow. The objective examination of the cervical rachis showed a decrease in mobility of the rachis in general and especially when rotating to the right. The patient felt sensible pain upon palpation of the spiny apophyses and on the right side of the neck at multiple levels (C2-C3, and C6-C7 above all). Cranial nerves and neurological examination were at normal levels also for upper limbs. Passive mobilization caused dizziness (light) and sense of nausea to appear.

Radiological examination of the cervical rachis showed that considerable formations of osteophysis in bridge form were present at the level of C5-C6 and C6-C7 with straightening of the cervical rachis (picture 3).

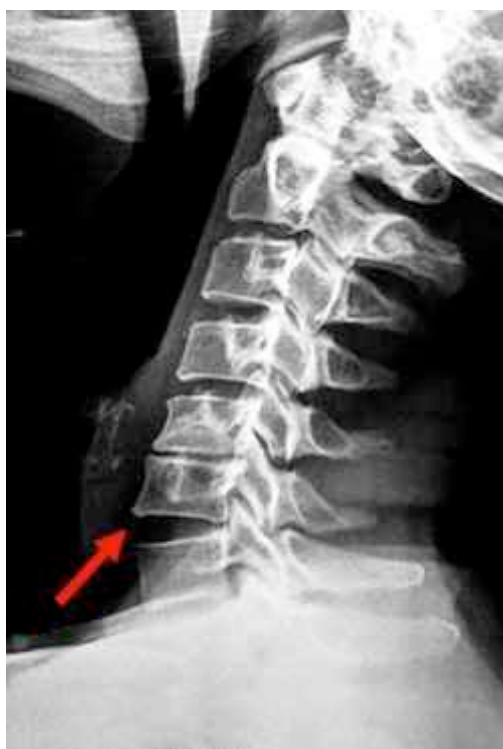

Fig.4.: Anterior somatic marginal osteophytosis with bone formation of bridges between the spinal bodies of C5-C6, C6-C7.

Irritation syndrome of nerve roots of C5-C7 to the right and joint dysfunction were diagnosed. Vertebrobasilar insufficiency was also taken into consideration, because the combination of neck extension and rotation caused dizziness and nausea. In this case no manipulation or mobilization of the neck was applied, avoiding also extension movement and advising the patient to use a semi-rigid cervical collar. Stimulation with TENS was applied, the electrodes were positioned to the sub-occipital level bilaterally (positive pole to the right) and on the right trapezium (distal negative pole). The stimulating unit was set to supply TENS, acupuncture-like, (frequency of 10Hz, impulse duration 250msec) for about 20 minutes.

After about 12 treatments the patient reported of a decrease in pain to the neck, while pain to the arm disappeared, joint limitation when rotating to the right and when leaning laterally to the right by 6 degrees remained, though.

DISCUSSION

One of the indications of TENS is the application for treating any type of local pain, somatic or neurogenic pain (for example radiculopathy). The most common application is for chronic pain of non malignant origin, but it can also be applied to pain of rheumatic origin, to post-traumatic and post-surgical pain. TENS is especially useful in the treatment of neurogenic pain connected to radiculopathy, compression syndromes, causalgia, peripheral nerves damage, as well as chronic lumbalgia and some painful conditions of arthritic origin.

Painful conditions of central and psychogenic origin and little pain, not very localised, do not respond to the treatment.

The purpose of the TENS is to obtain a "deep tingling" or a paresthesia, which would be comfortable for the patient, in order to reach a minimum muscular tensing. The decision on how to apply the electrodes is based on anatomical and physiological principles: the proximal electrode (anode) should be applied on the root of affected nerve; the distal electrode (cathode) should be positioned inside the corresponding dermatome or indifferently in the following way: along the nerve trunk, on the specific trigger point, on the area where the nerve passes more superficially (usually it coincides with the motor point), on the points of acupuncture, on the points of fibromyalgia, or on the algic points.

Generally the patient withstands also intensity and frequency at high levels (until 500Hz and 300usec of impulse duration). The stimulation time needed to produce analgesia varies according to the typology of TENS, the patient, the pathology and the treatment area. The use of adhesive electrodes in the second case caused a local reaction where the skin experienced reddening for about 2 days.

CONCLUSIONS

The reported clinical cases represent conditions that are common in the clinical outpatient practice, where optimal results can be obtained with TENS in addition to manipulation and to an adequate mobilization, where possible. The common factor is an irritation of the rachis that does not bring along serious neurological signs (paralysis, palsy, etc..).

The clinical study shows that TENS, if used intelligently, can prove to be a low risk technique, non invasive, relatively expensive and easily applicable (by expert personnel) to decrease the pain and, thus, improve functionality, or as a complement to other therapeutic techniques.

BIBLIOGRAPHY

1. Long, D M. Electrical stimulation for the control of pain. Arch Surg 1977; 112: 884-888.
2. Lampe GN. Introduction to the use of transcutaneous electrical nerve stimulation devices. Physical Therapy 1978; 58: 1450-1454.
3. Melzak R, Wall PD. Pain mechanisms: a new theory. Science 1965; 150:971-979.
4. Herman E. The use of transcutaneous nerve stimulation in the management of chronic pain. Physiotherapy Canada 1977; 29: 65-71.
5. Belanger AY. Physiological evidence for an endogenous opiate - related pain-modulating system and its relevance to TENS: a review. Physiotherapy Canada 1985; 37: 163-167.
6. FriedenberG ZB, Miller WT. Degenerative disc disease of the cervical spine. J Bone Jt Surg 1963; 45A: 1171.
7. Roche P, Wright A., An investigation into the value of TENS for arthritic pain. Physio. Theory & Practice 6;25-33 – 1990;
8. Alves-Guerreiro J, Noble G. et al., The effect of three electrotherapeutic modalities upon peripheral nerve conduction and mechanical pain threshold. Clinical Physiology 21(6): 704-711 – 2001;
9. Brosseau L., Milne S. et al., Efficacy of the transcutaneous electrical nerve stimulation for the treatment of chronic low back pain. Spine 27(6): 596- 603 – 2002;
10. Carrol E. N., Badura A. S., Focal intense brief transcutaneous electric nerve stimulation for treatment of radicular and postthoracotomy pain. Arch Phys Med Rehabil 82(2): 262-4 – 2001;
11. Abram SE. Transcutaneous electrical nerve stimulation, in: Neural Stimulation. Edited by Myklebust JB et al. Boca Raton, Florida: CRC Press Inc., 1985: 1 -10.
12. Loeser JD, Black RG, Christman A. Relief of pain by transcutaneous stimulation. J Neurosurg 1975; 42: 308-314.
13. Long DM. Electrical stimulation for relief of pain from chronic nerve injury. J Neurosurg 1973; 39: 718-722.
14. Melzack R, Vetere P, Finch L. Transcutaneous electrical nerve stimulation for low back pain. Physical Therapy 1983; 63:489-493.
15. Fried T, Johnson R, McCracken W. Transcutaneous electrical nerve stimulation: its role in the control of chronic pain. Arch Phys Med Rehabil 1984; 65: 228-231.
16. Mannheimer C, Carlsson CA The analgesic effect of transcutaneous electrical nerve stimulation (TNS) in patients with rheumatoid arthritis. A comparative study of different pulse patterns. Pain 1979; 6: 329-334.
17. Mannheimer JS. Electrode placements for transcutaneous electrical nerve stimulation. Physical Therapy 1978; 58: 1455-1462.
18. Leo KC, Dostal WF, Bossen DG et al. Effect of transcutaneous electrical nerve stimulation characteristics on clinical pain. Physical Therapy 1986; 2: 200-205.
19. Chesterton L. S., Foster N.E. et al., Effects of TENS frequency, intensity and stimulation site parameter manipulation on pressure pain thresholds in healthy human subjects. Pain 106(1-2): 73-80 – 2003;
20. Vasta A. : manuale clinico di terapia fisica . Minerva medica ed. 2008, Torino.
21. Vasta a. la stimolazione elettrica neuro-muscolare . Minerva Medica ed. , Torino ,2007.



MEDICAL ITALIA

EME's s.r.l. division.
Via degli Abeti 88/1
61122 Pesaro (PU) - Italy
Ph +39 0721 400 791 **Fx** +39 0721 26 385
info@eme-srl.com
www.eme-srl.com